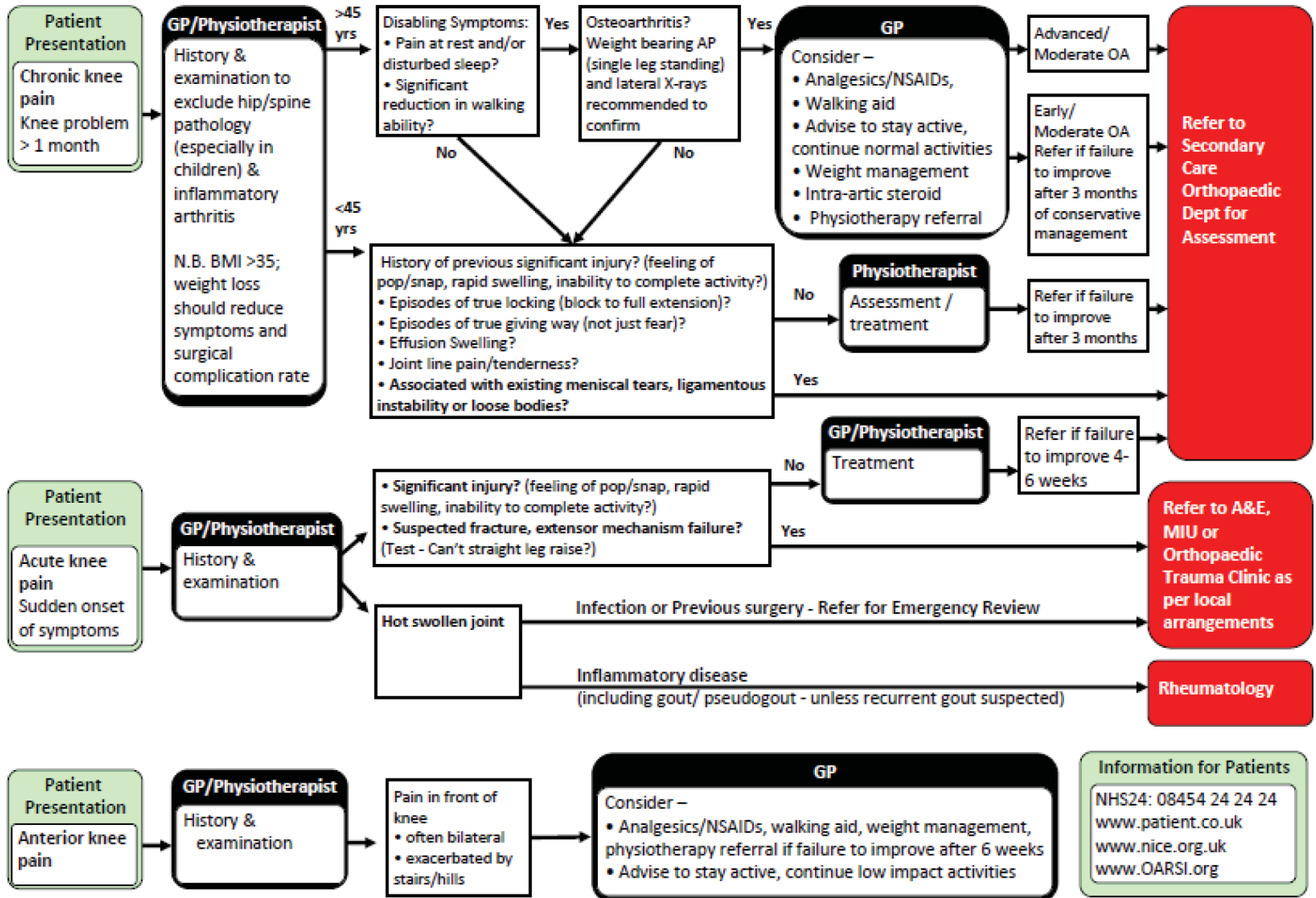


Musculoskeletal – Knee Pain Referral and Management Pathway



Musculoskeletal – Knee Pain Referral and Management Pathway

These guidelines are not intended to be exhaustive and allow for application of clinical judgement in individual situations.

Referral for Knee Imaging

Plain X-Rays

Indicated in the following situations:

- There is a history of acute trauma and associated knee swelling
- Patient remains unable to bear weight on the affected limb after knee injury
- Other situations where fracture is clinically suspected
- OA is suspected (patient over 45 or clinical signs indicative) N.B. Requires weight-bearing AP (single leg standing) /Lateral X-Rays
- Loose intra-articular body suspected

MRI

MRI is the most accurate non-operative method of diagnosing meniscal and ligament pathology.

It is indicated in the following situations:

- In suspected cases of meniscus and ligament injury
- In suspected cases of patellar dislocation where extensor mechanism injury is suspected
- Where there is doubt about diagnosis

N.B. Direct access to MRI for Knees by GPs and 'straight to test' (at vetting stage, pre-outpatients appointment) options are being piloted at a number of Boards. Once results have been evaluated this pathway may be updated.

Ultrasound Scanning

Ultrasound scanning may be indicated where there is the clinical suggestion of extensor mechanism injury.

Arthroscopy

Arthroscopy is the operative technique of choice for dealing with:

- Meniscus injury, particularly where there are mechanical symptoms or pain in keeping with symptomatic meniscus pathology. N.B. Meniscus pathology can occur at any age, even in the presence of mild OA.
- Cruciate reconstruction

- Other intra-articular pathologies (e.g. loose bodies, localised persistent joint line pain despite conservative management)

Arthroscopy should only be carried out after some form of pre-operative imaging of the knee, usually MRI. Arthroscopy may be appropriate where MRI findings are equivocal or diagnosis remains in doubt after scanning e.g. suspected lateral meniscus tears with persistent symptoms.

N.B. –

- Arthroscopy is not appropriate for meniscus pathology in the presence of moderate to severe OA.
- Arthroscopy for anterior knee pain is rarely indicated.
- Bi-lateral arthroscopy is rarely indicated and would always require pre-operative MRI scanning.
- Arthroscopy should not be routinely used for diagnostic purposes where non-invasive imaging may be more appropriate.
- Evidence is clear that arthroscopy with washout/debridement is not an appropriate treatment for established OA of the knee.

N.B. There is a national project to pilot community MSK service assessment/triage of MSK conditions. If your Board is involved in this, consider whether this condition could be assessed/triaged in this way.

Patient

Primary Care

Secondary Care

Useful Information for Patients

NHS24: 08454 24 24 24

www.patient.co.uk

www.nice.org.uk

www.OARSI.org